

## Sonographic Measurement of Spleen in Relation to Age: A Prospective Study in Adult Gujarati Population

Ramkumar Singhal<sup>1</sup>, S.M. Patel<sup>2</sup>, Madhuri Agrawal<sup>3</sup>, Srushti Rupareliya<sup>4</sup>, Dhara Patel<sup>5</sup>, Anuj Shrivastava<sup>6</sup>

### Abstract

The objective of the study is to assess the variation in splenic measurement like length, width and thickness in normal persons and categorise them according to different age group and sex using ultrasonography. This study was done on 500 individuals aged between 21-60 years. Ultrasonographic measurement of spleen was done by ESAOTE MYLAB 40 Machine. Measurement of spleen was taken by using convex 2.5-6.6 MHz probe. It was observed that the length decreased slowly with increase in age in both sexes. The width in male first it decrease then slightly increase and after that it again decreases. In female width slightly increases up to the age of 40 years, after 40 years of age it decreases slowly up to the age of 60. The thickness in male first decrease then slightly increases and after again decreases. In female first the thickness increases slowly after that it remains relatively constant, then decreases. All dimensions of spleen were greater in males than in females.

**Keywords:** Spleen; Ultrasonography; Hilum; Coronal Plane.

### Introduction

The spleen is a reticuloendothelial and lymphoid organ and sometimes works as hemopoietic organ. Otherwise this organ is graveyard of RBCs [2] situated in the upper left quadrant of the abdominal cavity between the fundus of stomach and diaphragm. Its shape varies from a slightly curved wedge to a 'domed' tetrahedron. The size and weight of the spleen vary with age and sex. It can also vary slightly in the same individual under different conditions. In the adult it is usually 12 cm long, 7 cm broad, and 3-4 cm wide. It is comparatively large in children, and although its weight increases during puberty [1].

The size of spleen is affected in various clinical conditions, most often due to reactive proliferation of lymphocyte or reticuloendothelial cell.

**Author's Affiliation:** <sup>1</sup>Assistant Professor, Dept. of Anatomy, Pacific Institute of Medical Science, Udaipur, Rajasthan 313015, India. <sup>2</sup>Professor <sup>4</sup>Associate Professor, Dept. of Anatomy, Govt. Medical College, Bhavnagar, Gujarat 364001, India. <sup>3</sup>Assistant Professor, Dept. of Pathology, Govt. Medical College, Bharatpur, Rajasthan 321001, India. <sup>5</sup>Tutor, Govt. Medical College, Surat, Gujarat 395001, India. <sup>6</sup>Medical Officer, Gandhidham, Gujarat, India.

**Corresponding Author: Dr. S.M. Patel**, Professor, Govt. Medical College, Bhavnagar, Gujarat 364001, India.  
E-mail: [drramkumarsinghal@gmail.com](mailto:drramkumarsinghal@gmail.com)

Received | 09.06.2018, Accepted | 22.06.2018

Splenomegaly is also caused by septicemia, malaria, kala-azar, CCF, cirrhosis, sarcoidosis, leukemias, lymphoma, Gaucher's disease, metastasis, secondaries, arsenic and phosphorus poisoning [2].

Many imaging techniques can be used to determine the size of spleen; ultrasonography is particularly useful because of the ease of use and lack of radiation exposure. Diagnostic imaging to assess spleen size is routinely accomplished by Ultrasonographic measurement along its long axis. However, there are variations among the radiological texts in defining the upper limits of normal for longitudinal diameter, with values ranging from 12 to 14 cm in adults. Normal spleen size has been found to vary significantly depending on age and sex [6].

We measured the splenic length, breadth and thickness in different age group and sex of adult population of Gujarat region of India and compared these measurements with those found in other reports.

### Materials & Methods

The present study is cross-sectional in nature and conducted in Government Medical College and Sir T. Hospital, Bhavnagar, Gujarat.

Before starting the study, prior permission of Professor and Head of Department, Anatomy and

Department of Radiology faculties was taken. Present study protocol was approved from the institutional review board [IRB (HEC) No.403/2014].

A prospective study will be conducted on 500 individuals aged between 21-60 years. Previous studies - as mentioned in references - have taken sample size of 160, but for more precise results, this study will be conducted on 500 individuals.

1. USG will be done by using Esaote My Lab 40 Machine.
2. Measurement of spleen will be taken by using convex 2.5- 6.6 MHz probe.
3. Individual will be positioned on coach in supine and right lateral position for examination with deep inspiration. Any USG scan suggestive of Splenomegaly was excluded.
4. Spleen will be measured at three dimensions (length, width and thickness).

*Length:* On longitudinal coronal image from dome to tip through hilum.

*Width:* On transverse coronal plane at hilum

*Thickness:* Longitudinal coronal plane at point bisecting the line indicating the length.

5. Following Splenic measurement were taken on USG scan:
  - Sonographic measurement of Splenic Length. (Fig. 1)
  - Sonographic measurement of Splenic Width.(Fig. 2)
  - Sonographic measurement of Splenic Thickness.(Fig. 3)

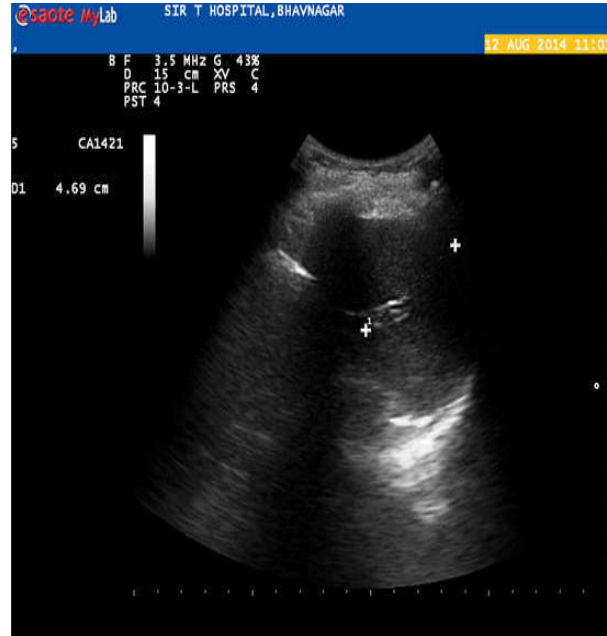


Fig. 2: Splenic width

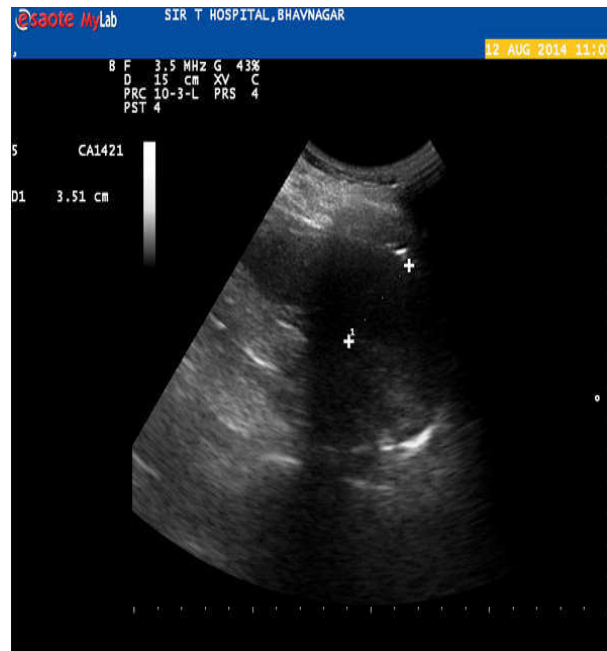


Fig. 3: Splenic thickness

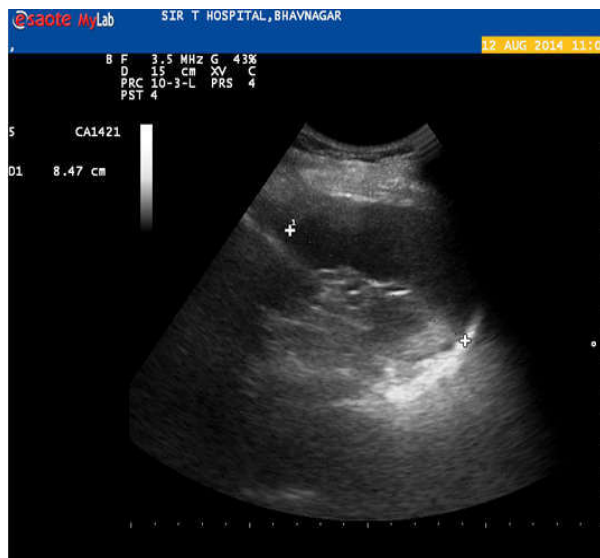


Fig. 1: Splenic Length

### Observations

500 USG Scans were studied and analyzed for Spleen measurement. There were 250 males (50%) and 250 females (50%) with age range of 21-60 years in Govt. Medical College & Sir T. Hospital Bhavnagar.

The statistical data which were extracted from the calculation and analysis are tabulated in Table-1 to Table-6 to show different parameters at a glance.

**Table 1:** Splenic length in different age groups in Male

Age	N	Mean(cm) ± SD	Range (cm)	Correlation coefficient
21-30	70	10.08429± 0.983485	7.92- 11.90	r = 0.2522
31-40	57	9.997895 ± 1.018861	7.56 - 11.83	r <sup>2</sup> =0.06360
41-50	62	9.938871± 0.739633	7.97 - 11.9	P value<0.0001
51-60	61	9.482787± 1.212961	6.59 - 11.54	

**Table 2:** Splenic length in different age groups in Female

Age	N	Mean(cm) ± SD	Range (cm)	Correlation coefficient
21-30	102	9.380392 ± 1.125987	6.83-11.84	r = - 0.04181
31-40	75	9.574667 ± 0.986129	7.2 - 11.93	r <sup>2</sup> = 0.001748
41-50	46	9.288043 ± 1.127803	7.17 - 11.4	P value= 0.5105
51-60	27	9.241111 ± 1.183432	7.15 - 11.59	

**Table 3:** Splenic Width in different age groups in Male

Age	N	Mean(cm) ± SD	Range (cm)	Correlation coefficient
21-30	70	4.575652 ± 0.712367	2.94- 6.23	r =- 0.01124
31-40	57	4.464386 ± 0.66776	3.15- 6.31	r <sup>2</sup> = 0.01264
41-50	62	4.590161 ± 0.739633	3.08 - 6.53	P value: 0.0754
51-60	61	4.279672 ± 0.760467	2.92 - 6.07	

**Table 4:** Splenic Width in different age groups in Female

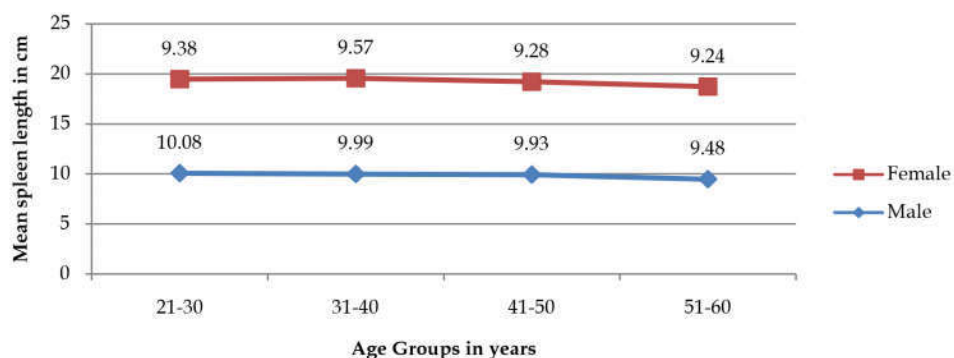
Age	N	Mean(cm) ± SD	Range (cm)	Correlation coefficient
21-30	102	4.174216 ± 0.68292	2.88-5.82	r = 0.01672
31-40	75	4.332133 ±0.785709	2.6-6.42	r <sup>2</sup> = 0.0002795
41-50	46	4.138478 ± 1.127803	2.57- 6.61	P value 0.7921
51-60	27	4.078148 ± 0.693104	2.91 - 6.46	

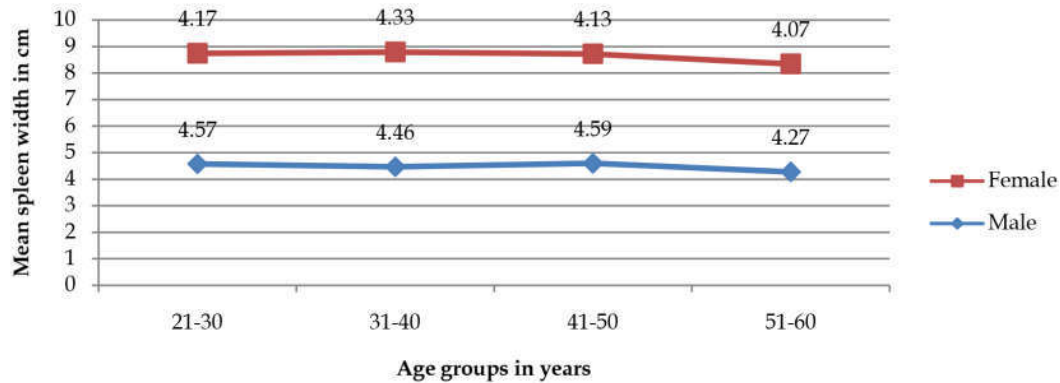
**Table 5:** Splenic Thickness in different age groups in Male

Age	N	Mean(cm) ± SD	Range (cm)	Correlation coefficient
21-30	70	3.538 ± 0.683333	2.07-5.23	r = -0.09614
31-40	57	3.425965 ± 0.616974	2.45-4.77	r <sup>2</sup> =0.009242
41-50	62	3.58629 ± 0.678871	2.25-5.52	P value: 0.1288
51-60	61	3.40541 ± 0.6377	2.05-5.65	

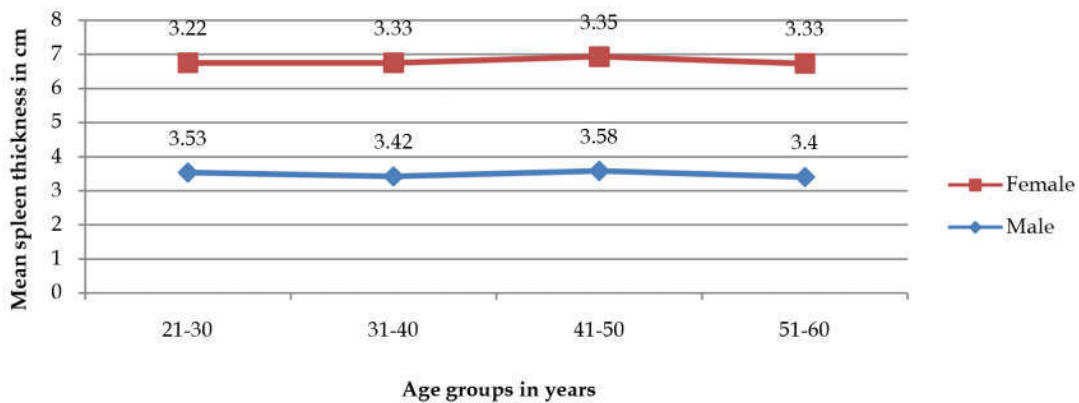
**Table 6:** Splenic Thickness in different age groups in Female

Age	N	Mean(cm) ± SD	Range (cm)	Correlation coefficient
21-30	102	3.22402 ± 0.606929	2.1- 4.65	r = -0.06648
31-40	75	3.334133 ± 0.645994	2.14 - 5.09	r <sup>2</sup> = 0.004420
41-50	46	3.352391 ± 0.727911	1.7- 4.63	P value: 0.2941
51-60	27	3.252963 ± 0.564527	2.2 - 4.77	

**Graph 1:** Change in spleen length in relation to sex



Graph 2: Changes in Spleen width in relation to sex



Graph 3: Changes in Spleen thickness in relation to sex

## Discussion

The splenic size may give information about the diagnosis and course of the gastrointestinal and hematologic disease [14]. In one study the splenic size was evaluated in patients with sarcoidosis and thrombocytosis, the splenomegaly was present in 57% of the patients (using sonographic criteria to evaluate the size), but only clinically palpable in 8% of the cases.

In the present study, it was observed that the splenic length decreased with age in both males and females. The splenic length decreased at a slow rate up to the age of 60 years. This was relatively different to the findings of Loftus and Metreweli. They observed rapid growth in the splenic length up to the age of 20 years followed by a mild decrease up to the age of 50 years and then rapid fall after the age of 50 years (Graph 1).

In the present study, it was observed that the splenic length was found to be less than 11 cm in most of the subjects. This was similar to the findings of Frank et al. [10].

In the Arora et al. [4] study, they observed that splenic length decreased slowly up to the age of 50 years and after 50 years rapid fall is seen in both sex. In present study, the splenic length was decreased slowly up to the age of 60 years, this was different from Arora et al. [4] the splenic width decreases up to the age of 30 years, after 30 years it remain relatively constant up to the age 50 years and after that splenic width decreased. In present study up to the age of 40 years splenic width decrease slowly, with increase in age. After 40 years it slightly increases up to the age of 50 years, then after 50 years it decreases up to the age of 60 years (Graph 2).

Splenic thickness was constant up to the age of 50 yrs, after which there was a fall in the splenic thickness. Arora et al. [4] In our study in the males up to the age of 40 years splenic thickness decreases. After 40 years splenic thickness slowly increases up to the age of 50 years and After 50 years splenic thickness decreases. In the female up to the age of 40 years splenic thickness increases slowly after that up to the age of 50 years it remain relatively constant. From the age group 51 to 60 years splenic thickness decreases (Graph 3).

Rosenberg et al. [11] studied that the upper normal limit of the splenic length was observed to be 12 cm for girls of 15 years or more and 13 cm for boys of 15 years or older. These findings were slightly different from the findings of the present study. This difference may be due to the genetic factors, nutritional factors or the environmental factors.

In another study the mean longitudinal diameter of the spleen was found to be  $5.8 \pm 1.8$  cm and transverse diameter  $5.5 \pm 1.4$  cm. These dimensions were much smaller than those of present study because the authors did not measure the maximum length of the spleen [14].

The splenic width and thickness were observed to be less than 6 cm and 4 cm respectively in most of the subjects in the present study. This was different from the findings of Frank K, who observed the splenic width below 7 cm and thickness below 5 cm in most of the subjects [10].

In Bihari population the length of spleen increased with increase in the height in both male and female. Splenic length was determined by ultrasonography. In our study splenic length decreased slowly with increase in the age up to 60 years [17].

Udoaka AI, et al. [19] described that the length of spleen in ages ranging from 18 to 40 years was  $9.23 \pm 1.53$  cm. In present study the length of spleen in this age group was  $10.03 \pm 0.99$  cm. This difference was slightly from Udoaka. This difference may be due to the genetic factors, nutritional factors or the environmental factors.

Spielmann et al, have studied that the average length of spleen was found in athlete  $11.4 \pm 1.7$  cm in males and  $10.3 \pm 1.3$  cm in females. The spleen length was greater male athlete than female [30]. In our study mean splenic length for male is  $9.87 \pm 0.98$  cm and for female  $9.36 \pm 1.10$  cm. The length is greater in male than female but the mean value of length is lesser than the Spielmann study.

## Conclusion

In the present study an attempt has been made to determine the normal range of the length, width and thickness of the spleen and to correlate these dimensions with the age in male and female subjects. The splenic length in both male & female is significantly correlate with the age while width is relatively significant in both sex and thickness is not correlate with age in either of sex. By this study we find that ultrasonography is the current

procedure of choice for routine assessment of spleen size (normal = a maximum cephalocaudal diameter of 13 cm) because it has high sensitivity and specificity and is safe, noninvasive, quick, mobile, and less costly.

## References

1. Susan Standring, Harold Ellis, Healy JC, David Johnson, Andrew Willims, Barry KB, Neil RB, et.al. Spleen. Gray's anatomy, (40<sup>th</sup> edition); page no. 1191.
2. Dhingra B, Sharma S, Mishra D, Kumari R, pandeyRM, Aggarwal S. Normal values of liver and spleen size by Ultrasonography in Indian children. Indian pediatrics 2009;03:1 -6.
3. Rayhan KA, Ara S, Nurunnabi Asm, Kishwara S, Noor M. Morphometric Study Of The Postmortem Human Spleen. J Dhaka Med Coll, 2011;20(1):32-36.
4. Arora N, Sharma PK, Shai A, Singh R, "Sonographic Measurement of The Spleen in Relation to Age; A Prospective Study In North Indian Adults. J. Anat. Soc. India. 2010;59(2):177-181.
5. Petzoldt R, Lutz H, Ehler R, Neidhardt B. Determination of splenic size by ultrasonic Scanning. Med Klin. 1976;26.71(48):2113-6.
6. Hosey RG, Mattacola CG, Kriss V, Armsey T, Quarles JD, Jagger J, Ultrasound assessment of spleen size in collegiate athletes; Br. J. Sports Med. 2006;40:251-254.
7. Susan Standring, Harold Ellis, Healy JC, David Johnson, Andrew Willims, Barry KB, Neil RB, et.al. Spleen. Gray's anatomy, (39<sup>th</sup> edition); page no. 1192.
8. Dittrich M, Milde S, Dinkel E, Baumann W, Weitsel D. Sonographic biometry of liver and spleen size in childhood. Pediatr Radiol 1983;13:206-211.
9. Keith LM, Persaud TVN. Development of Spleen. The developing human clinically oriented embryology, (8<sup>th</sup> edition). page no. 223.
10. Frank K, Linhart P, Kortsik C, Wohlenberg H. Sonographic determination of the spleen size: normal dimensions in adults with a healthy spleen. Ultraschall Med. 1986;7(3):134-7.
11. Rosenberg HK, Markowitz RI, Kolberg H, Park C, Hubbard A, Bellah RD. Normal splenic size in infants and children: sonographic measurements. Am J roentgenol 1991;157(1):119-21.
12. Anger K, Gelinsky P, Lagemann K. Determination of spleen size by roentgenographic and nuclear medicine methods: Radiologe. 1976 Apr;16(4):128-34.
13. Frank H, Deland. Normal Spleen Size. Radiology 1970; 589-2.
14. Niederau C, Sonnenberg A, Muller JE, Erckenbrecht JF, Scholten T, Fritsch WP. Sonographic measurements of the normal liver, spleen, pancreas and portal vein. Radiology 1983;149(2):537-40.

15. Schindler G, Longin F, Helmschrott M. The individual limit of normal spleen size in routine x-ray film. *Radiologe* 1976;16(4):166-71.
  16. Singh A, Ansari H, Das JK, Chandra N. Ultrasonographic Measurement of Splenic length in relation with Height in Bihari Adult population a prospective study. *J. Anat. Soc. India*. 2011;60(2):188-89.
  17. Lamb PM, Lund A, Kanagasabay RR, Martin A, Webb JAW, Reznik RH. Spleen size: how well do linear ultrasound measurements correlate with three-dimensional CT volume assessments. *The British Journal of Radiology*, 2002;(75):573-77.
  18. Udoaka AI, Enyi C, Agi CE. Sonological Evaluation of the Liver, Spleen and the Kidneys in an Adult Southern Nigerian Population. *Asian Journal of Medical Sciences*. 2013;5(2):33-36.
  19. Kaya SARAC, Ramazan KUTLU, Cengiz YAKINCI, Yasar DURMAZ, Tamer BAYSAL, Unsal OZGEN. Sonographic evaluation of Liver and Spleen size in School age children. *Turk J Med. Sci*. 2000;(30):187-90.
  20. Okoye IJ, Agwu KK, Ochie K. Sonographic Splenic size in normal adult Nigerian population. *West African journal of Radiology*. 2005;12(1):37-43.
  21. Asghar A, Naaz S, Agrawal D, Sharma P.K. Morphometric study of Spleen in north Indian adult population: CT Scan image based study. *Journal of Clinical and Diagnostic Research*. October 2011; Vol-5(5):974-77.
  22. Rayhan KA, Ara S, Nurunnabi A, Kishwara S, Noor M. Morphometric Study of The Postmortem Human Spleen. *J Dhaka Med Coll*. 2011 April ;20(1):32-36.
  23. Asghar A, Agrawal D, Yunus SM, Sharma PK, Zaidi SHH, Sinha A. Standard Splenic Volume Estimation in North Indian Adult population: Using 3D Reconstruction of CT Scan image. *Hindawi Publishing Corporation Anatomy Research International*. 2011; 2011:1-5.
  24. Mustafa ZM, Splenic Weight versus Body Height and Weight in Sudanese Adults By Using Ultrasound. *Asian Journal of Radiological Research*. Jan-June 2013;1(1):56-59.
  25. Mustapha Z, Tahir A, Tukur M, Bukar M, Lee WK. Sonographic determination of normal spleen size in an adult African population. *European Journal of Radiology (Impact Factor: 2.65)*. 2009 Oct;75(1):133-5.
  26. Ehimwenma P, Tagbo MT, Determination of normal dimension of the spleen by ultrasound in an endemic tropical environment. *Journal of the Nigeria Medical Association*. 2011 Jul;52(3):198-203.
  27. Al-Imam O, Suleiman A, Khuleifat S. Ultrasound Assessment of Normal Splenic length and Spleen to Kidney Ratio in Children. *East Mediterr Health J*. 2000 Mar-May;6(2-3):514-6.
  28. Safak AA, Simsek E, Bahcebasi T. Sonographic assessment of the Normal Limits and Percentile Curves of Liver, Spleen, Kidney Dimensions in Healthy School -Aged Children. *J Ultrasound Med*. 2005;24: 1359-1364.
  29. Megremis SD, Vlachonikolis IG, Tsilimigaki AM. Spleen Length in Childhood with US: Normal Values Based on Age, sex and Sometometric Parameters. *Radiology*. 2004 Apr;231(1):129-34.
  30. Spielmann AL, DeLong DM, Kliewer MA. Sonographic evaluation of spleen size in tall healthy athletes. *AJR Am J Roentgenol*. 2005 Jan;184(1):45-9.
-